

# Displacement of lower third molar into parapharyngeal space. Case report

## Case Report

*Khurshid A. Kheder Khrwatany*

*Assistant Professor, Senior Academic Member in department of Oral and maxillofacial surgery, college of dentistry, Hawler Medical university*

---

## ABSTRACT

Surgery of lower third molar may be accompanied by many complications. One of these complications which has been documented in literature is its displacement lingually. In this case report, the tooth was displaced into an area between submandibular salivary gland, root of the tongue and upper portion of pharynx. The incidence happened during trial of third molar extraction by general practitioner dentist. The cause of such complication may be heavy force application during closed extraction using elevator. Patient presented with trismus, swelling and dysphagia. Under general anesthesia trial of removal by intraoral approach done but failed. Through extraoral approach the tooth and a piece of fractured bone removed from mentioned space. Antibiotic therapy and palliative therapy gave positive effect after 48 hours from surgery and complete subsiding of signs and symptoms after 10 days from surgery. Conclusion: for partially and completely impacted third molar removal the best option is open surgery and controlled force. This tooth better to be removed by oral surgeon to have ability to control possible complications.

**Key Words:** Third molar, Tooth displacement, Dental surgery, Dental extraction complication.

**Received:** 22 December 2023, **Accepted:** 2 February 2024.

**Corresponding Author:** Khurshid A Kheder Khrwatany, Assistant Professor, Senior Academic Member in department of Oral and maxillofacial surgery, college of dentistry, Hawler Medical university **Mobile:** +964 750 448 88 11, **E-mail:** khurshid.khrwatany@khcms.edu.krd

**ISSN:** 2090-097X, April 2024, Vol. 15, No. 2

## INTRODUCTION

Surgery of lower third molar (LTM) can be associated with some complications. Pain, swelling, dry socket, infection, bleeding, numbness and/or paraesthesia of lower lip and displacement of the tooth to surrounding spaces in literature reported to be about 1%. Common spaces are prerygomandibular, sublingual and submandibular and lateral pharyngeal [1]. The causes of this complication are numerous, but anatomic considerations, such as distolingual angulation of the tooth or dehiscence in lingual cortical plate, inexperience, excessive or uncontrolled force, improper manipulation and inadequate clinical and radiographic examination are important factors that can lead to tooth displacement [2, 3].

Clinical presentation of such complication varies from simple discomfort and pain to swelling, trismus and dysphagia [1]. These signs and symptoms are going to determine the course of treatment.

## CASE REPORT

A case of 32 years old female referred to our clinic with referral note displaced third molar of left side into parapharyngeal space 48 before presentation to our clinic. She was complaining of trismus (0.5 cm vertical distance between incisal edges of upper and lower jaw; pain; dysphagia and extra oral swelling at submandibular area. According to history was displaced during trial of

closed extraction by general dental practitioner. After the incidence, he asked another dentist to remove it. The second one tried to remove it through introral incision at retromolar area. The trial failed and the tooth further pushed away both posteriorly and inferiorly. Then they sutured the site; antibiotics and analgesics prescribed (Amoxiclav capsules 625mg twice /day and Diclofenac tabs 75 mg on need); the patient sent to our clinic.

On computer tomography we found that the tooth and a piece of bone were located at an area between posterior pole of submandibular salivary gland, root of the tongue and the anteriolateral wall of upper pharynx. (Figure 1).

We started treatment with antibiotics (ceftriaxone vial 1gm twice/day and Metronidazol bottle 500 mg three times/day), analgesics (paracetamol bottle 500 mg on need) and training to open the mouth by tongue depressors for 24 hours. After 24 hours she could open about 1.5 cm. The intubation done through laryngo-video-scope and general anesthesia achieved.

Through existing intraoral incision we tried to remove it but we could not feel it. Decision made to remove it through submandibular approach. The tooth was located just like the CT showed (at an area between posterior pole of submandibular salivary gland, root of the tongue and the anteriolateral wall of upper pharynx). Both the tooth

and a piece of bone removed the site (Figure 2), Irrigation and hemostasis done and the site sutured layer by layer.

The patient was discharged 24 hours after the surgery with some improvement on the same treatment plus Dexamethasone ampule 8 mg twice day for three days. On follow up visit on 3rd postoperative day, the patient was able to open 3 cm, pain and dysphagia were better, but swelling was still noticeable. On tenth postoperative day the patient was completely free of signs and symptoms apart from tens sensation at the site of operation. Sutures removed and regular follow up recommended.

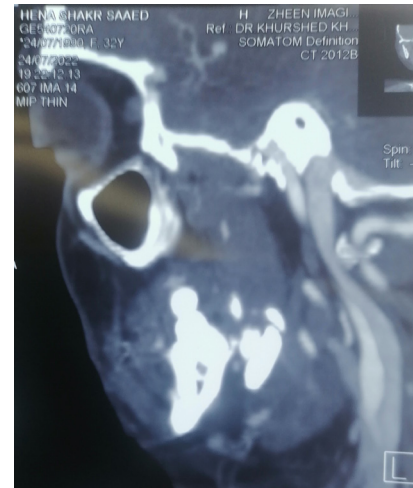


Figure 1 c

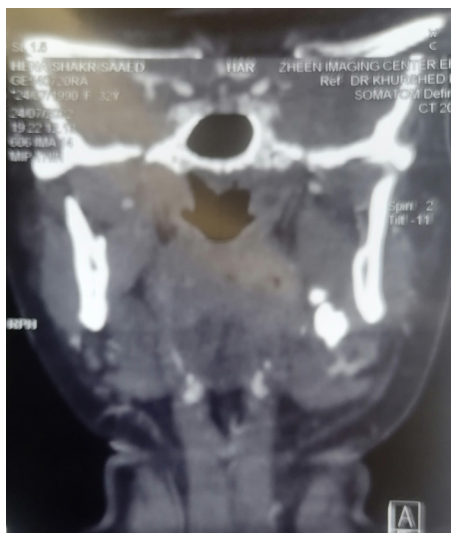

Figure 1 a

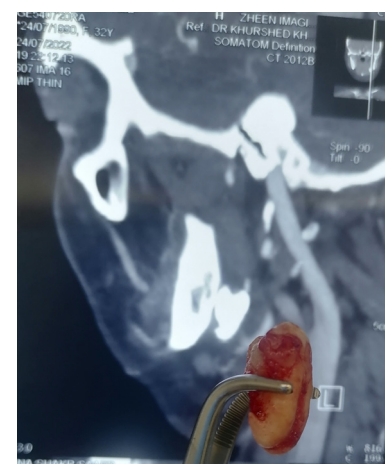


Figure 2

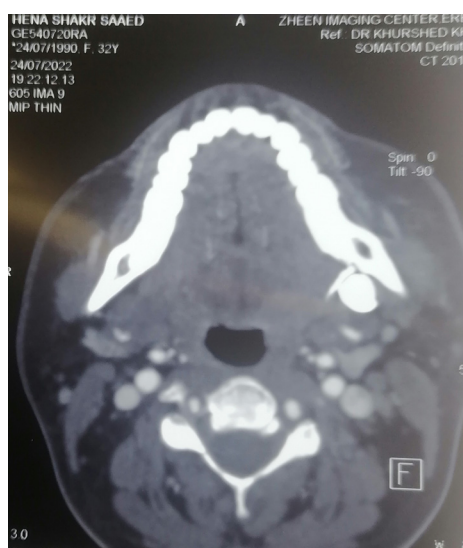


Figure 1 b

## DISCUSSION

Majority of complications associated with LTM surgery may come from improper preoperative examination and preparation. Both mentioned factors may be noticed as a part of practicing inexperienced and/or overconfident dentists or surgeons. This moment has been mentioned by many authors; however, absence of prospective and experimental studies makes this point just a preposition. From the point of mechanism of happening we can suggest that improperly directed and applied force moves the tooth or its segments to lingual side when it can easily move into available spaces. Factors that may help this displacement may be reflecting of lingual soft tissue from the bone; weak lingual plate of bone and lingually curved roots. In our case both factor of inexperience and weak lingual plate were available. The trismus accompanied our case was partly because of displaced tooth with irritation, but the main factor was the trial of removal intraorally that lead to both hematoma and damage to fibers of medial pterygoid muscle. This clinical presentation further complicates the case, because of difficulty of access through intraoral approach and difficulty of intubation for general anesthesia. The condition was properly managed by analgesics and training.

Absence of pus in the site possibly was due to absence of infection at the site before surgery and prescription of antibiotics directly after the incidence. Despite the fact that there is recommendations to extract infected teeth immediately,<sup>[4]</sup> infected third molars should not be extracted by general dental practitioners, but send it to oral surgeons. If this rule applied the chances of displacement and other complications associated with this procedure will be decreased to minimum. Even if displacement happened there is less chances of infection post operatively.

### **CONCLUSION**

---

Impacted third molar teeth should not be extracted by general dentists. Trials for closed extraction of partially impacted teeth should be prohibited. If the tooth displaced, the trial of removal should be done as fast as possible by oral or maxillofacial surgeons.

### **Conflicts of interest**

There are no conflicts of interest

### **REFERENCES:**

---

1. Oliveira MMM, da Franca Acioly R, de Souza DD, da Silva BA, Carvalho DDC. Third Molar Displacement into Submandibular Space. *Case Reports in Dentistry*. 2019;2019:6137868.
2. Kamburoglu K, Kursun S, Oztas B. Submandibular displacement of a mandibular third molar root during extraction: A case report. *Cases journal*. 2010;3:8.
3. Jolly SS, Rattan V, Rai SK. Intraoral management of displaced root into submandibular space under local anaesthesia –A case report and review of literature. *The Saudi Dental Journal*. 2014;26(4):1814-.
4. Isik K, Gürses G, Menziletoglu D. Acutely infected teeth: to extract or not to extract? *Brazilian Oral Research*. 2018;32.