

“The Accuracy of Mimic Software compared to AutoCAD Software in The Evaluation of the Volumetric Reduction of Maxillofacial Cystic Lesions after Marsupialization: A prospective comparative study.”

Mohamed M. Ghoneim ¹, Hamed Gad ²

Department of Oral and Maxillofacial Surgery Faculty of Dentistry Sinai University¹,
Department of Oral and Maxillofacial Surgery Faculty of Dentistry Minia University²

ABSTRACT

Background: A growing body of evidence has recently utilized 3D assessment to follow up on the volume reduction after marsupialization of maxillofacial cysts and the need for enucleation. Materialise Mimics software has been widely used for that purpose. Recently, computer-aided design (AutoCAD) has proven its reliability in assessing the change in cyst volume in a wide range of surgeries.

Purpose: To compare the accuracy of two computer programs (commercial computer-aided design (AutoCAD) and Materialise Mimics) in measuring the volume reduction of cysts post marsupialization.

Materials and Methods: We conducted a case-series study on 15 patients with radicular cysts who underwent marsupialization. The determination of cyst measured volume was carried out using AutoCAD and Mimics pre-operatively and up to nine months after the procedure.

Results: Using AutoCAD software, the volume (mm³) estimated and average (\pm SD) of 29037.9, 13759.9 \pm 10137.8, 94.994 \pm 3303.7 \pm 1984.4, 4579.1 \pm 3276.6 mm³ in pre-marsupialization, 3-, 6-, and 9-months post-marsupialization; respectively. With Mimics software, the volume (mm³) recorded an average (SD) of 29041.04579.0 \pm 3275.0, 13761.4 \pm 10144.6, 94994.5 \pm , and 1984.63303.9 \pm mm³ in pre-marsupialization, 3-, 6-, and 9-months post-marsupialization; respectively. The difference between measures carried out by MIMIC and AutoCAD software was non-significant ($p > 0.05$) at all checked follow-up time points (pre-, 3-, 6-, 9- months post-marsupialization)

Conclusion: Computer-aided (AutoCAD) assessment of post-marsupialization volume reduction of maxillofacial cysts is a readily available, easy-to-use, cheap, and accurate option to be contemplated along with Mimics software.

Key Words: Cystic Lesions; Marsupialization; AutoCAD, Mimics

Received: 20 June 2021, **Accepted:** 9 August 2021.

Corresponding Author: Mohamed M. Ghoneim, Instructor at Oral & amp Maxillofacial Surgery, Department. Faculty of Dentistry. Sinai University, Egypt, **Tel :** 0862338474, **Mobile:** 201002862224, **E-mail:** mohamed.moawed@su.edu.eg.

ISSN: 2090-097X, July 2021, Vol. 12, No. 3

INTRODUCTION

The description of maxillofacial cystic lesions backs to Ancient Egypt since 4500 B.C ^[1]. Nonetheless, it was not until the early 1900s, in which a growing number of published literature has tried to explore the clinical presentations and management of maxillofacial cystic lesions^[2]. Maxillofacial cysts are common,

non-infectious, pathological cavity composed of fluid or gases and surrounded -partially or entirely- by an epithelial layer^[3]. They are usually classified into malignant cysts or pseudocysts, with overlapping clinical features and radiological appearances^[4].

Maxillofacial cysts can occur secondarily to a wide range of causes, such as malignancy, trauma, inflammatory conditions, and developmental disorders; the cysts usually appear during adulthood, and they are more common among females ^[5]. While a considerable proportion of maxillofacial cysts are asymptomatic and accidentally discovered, patients may present with persistent pain,

swelling, paraesthesia, teeth displacement, and pathological fractures^[6]. Besides, malignant cysts exhibited highly aggressive behavior and frequent recurrence^[4]. Therefore, complete cyst removal is the main goal of treatment to ensure low recurrence probability^[7]

The choice of surgical technique for removing maxillofacial cysts depends mainly on the size of the cysts. Small cysts can be easily eradicated by enucleation or curettage with a low recurrence rate and postoperative morbidity ^[5]. On the other hand, radical resection is usually preserved for large cysts due to high recurrence and pathological fractures ^[8]. Marsupialization is a surgical procedure that donates relieving intracystic pressure through an opening to allow for drainage; the technique is based on converting the cyst into a pouch by communicating the cyst with oral mucosa^[9].

In return, marsupialization allows a gradual reduction in the cyst size and stimulates bony classification of the cyst wall^[10]

Marsupialization has gained much popularity over the years for the management of large cysts owing to the low risks of associated injuries to vital structures and fractures. Besides, the technique enhances osteogenesis and improves pulp vitality [11]. However, the need for enucleation for healing and the long follow-up period are the main disadvantages of marsupialization.

Three-dimensional (3D) imaging is the modality of choice for preoperative assessment of cyst volume and diameter; previous reports demonstrated that 3D computed tomography (CT) could accurately measure the cyst volume, demonstrate the cyst border, and evaluate the anatomical relations of the cyst [12]. A growing body of evidence has recently utilized 3D assessment via Materialise Mimics software to follow up on the volume reduction after marsupialization of maxillofacial cysts and the need for enucleation [12,13]. Recently, computer-aided design (AutoCAD) has proven its reliability in assessing the change in cyst volume in a wide range of surgeries [14]. This study aims to evaluate the accuracy of AutoCAD and Mimics software in the 3D assessment of volume reduction of cysts following marsupialization.

MATERIAL AND METHODS

The protocol of the study was approved by the Ethical Committee of the Faculty of Dentistry, Sinai University. The details of the treatment plan and methodology of the study were explained to each individual patient, and written informed consents were collected prior to surgical intervention. We confirm that none of the study's procedures violated the main principles of the Declaration of Helsinki [15].

2.1 Sample size calculations :

The sample size was calculated by power analysis using power version 3.1.9.6. to evaluate the difference in accuracy between the two programs and their different values in relation to the position of the lesion; a repeated measure ANOVA was proposed. A total sample size of 15 patients was sufficient to detect an effect size of 0.25 at a power of 0.9 (90%) at a significance level of 0.05. Each method AutoCAD, Mimics groups was applied on 15 patients [15,16]

2.2. Study design and Patients :

We conducted a case-series study on 15 patients with radicular cysts of more than 1000 mm³ volume who underwent marsupialization. The series of patients were selected from the outpatient clinic of Oral and Maxillofacial Surgery Departments in both Minia and Sinai Universities. Patients aged between 10 to 50 years old were recruited regardless of their gender. Only patients with large intra-bony cystic lesions, which was defined as cyst volume > 1000mm³ and confirmed by histopathological examination, were included. We excluded

patients with other systemic or localized bony diseases and patients who were not willing for follow up visits.

2.3. Preoperative Assessment:

Complete medical reports of all eligible patients were established, including patients' general and specific medical and dental history. Besides, the cysts characteristics were collected through intra-oral examination. All the patients within this study were primarily examined pre-operatively by digital

ortho-panorama (OPG). Afterwards, Multi-slice CT scans were performed preoperatively and postoperatively for each patient to determine the extension of the cyst, presence of impacted teeth or odontoma, the proximity of the cyst margins to the maxillary sinus or other vital structure.

2.4. Determination of cyst measure volume using AutoCAD and Mimics.

The determination of cyst volume using AutoCAD (v2020, Autodesk, Inc. Mill Valley, CA, USA) was measured by assessing the volume of the cyst on CT with 1mm slice, then measuring the volume of every slice by volume = area x depth. Then, the sum of the volume of each slice was calculated to determine the cyst volume. Mimics 21.0 (Materialise NV, Leuven, Belgium) software was also used to measure the same slices by reconstructing them into a 3D structure and calculating the volume. Measurements were done pre and 3, 6, 9 months post-marsupialization.

2.5. Surgical Procedures:

Preoperative prophylactic antibiotics were prescribed according to body weight and history of sensitivity. The patients were asked to thoroughly rinse with Povidone-iodine 10% disinfectant solution before surgical procedure. Isolation and draping of the patient were performed according to the standard technique for intraoral surgeries. All the surgical procedures of marsupialization were performed under local anaesthesia in the outpatient clinic. An incisional biopsy was performed simultaneously.

A scalpel was stabbed directly through the oral mucosa, and the underlying cyst lining against the bone edge and an opening was made into the sac by cutting from inside the cavity out against the bone margin. Then the cyst lining specimen was sent for histopathological study. The margins of the oral mucosa and the cyst lining were sutured together. Irrigation in the cyst cavity with saline and suction the saline and the cyst fluid (Figure 1). Impression was taken extended into the cystic cavity using alginate impression material and send to the dental laboratory for plug fabrication.

Suturing of the periphery of each cyst lining to the oral mucosa and each cavity was packed with a gauze drain, which changed daily by the patient himself for the first week of post-marsupialization.

All patients received oral antibiotic therapy according to body weight and history of sensitivity post-marsupialization. Non-steroidal anti-inflammatory drugs were also recommended as needed. The patients were ordered postoperatively to adhere to a soft diet for the first week. Oral hygiene maintained by twice-daily rinsing with 0.2 % chlorhexidine mouth wash and two to three daily saline irrigations of the cystic cavity by the patient himself. The patients were taught how to care for the plug.

The follow-up was performed at the first four weeks and then every three months until the end of the proposed post-marsupialization follow-up period. Multi-slice CT scan (coronal, axial and sagittal cuts) at three, six, and nine months post-marsupialization was performed on all patients (Figure 2).

2.6. Statistical analysis:

Statistical analysis is to be carried out to evaluate the difference in accuracy between the two programs and their different values in relation to the position of the lesion (maxilla or mandible, anterior and posterior).

Friedman's test was applied to evaluate the difference in volume between different timepoint within each method (mimic or AutoCAD), Mann-Whitney test statistic was used to check the difference between Mimic and AutoCAD volume readings at each time point.

Repeated measures ANOVA were applied to study the overall effect of groups and timepoints and their interactions at 0.05 level. Simple linear regression and regression trendline was applied to assess the change of volume with postoperative follow-up time points^[18,20]

RESULTS

Fifteen 15 patients were studied in estimation by either MIMIC or AutoCAD software in current research. The measurements from each software were recorded twice by the same examiner with a two-week interval between them, the results of (insert intra-rater reliability test here) was (positive). 53.3% of the samples were male, and 46.7% were females, and the difference was non-significant ($p>0.05$ ns) as revealed by the Chi-square test. The average(\pm SD) age among patients was 34.13 ± 9.59 years, where it ranged between 20 to 47 years. About 60% of the patients were anterior, 40% posterior, where the anterior mandible was 26.7 % (n=8), posterior mandible comprised 6.7% (n=2), anterior and posterior maxilla comprised about 33.33 % (n=10). The difference among the sites of the study were also non-significant ($p<0.05$) (Table, 1).

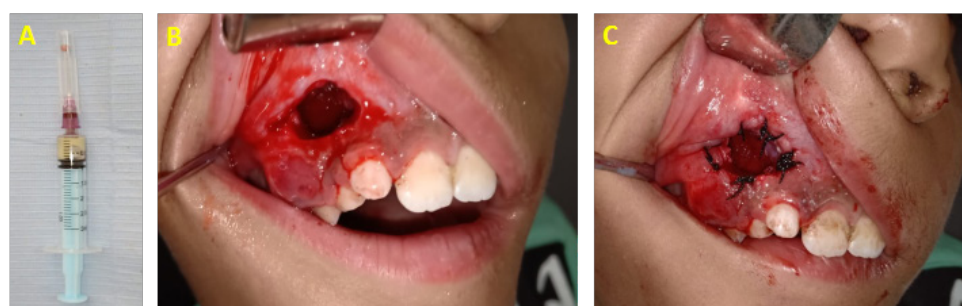


Figure 1. (A) Aspirated cystic fluid, (B) Intraoperative photograph showing window after marsupialization, (C) Intraoperative photograph after suturing of cyst wall and mucosa.

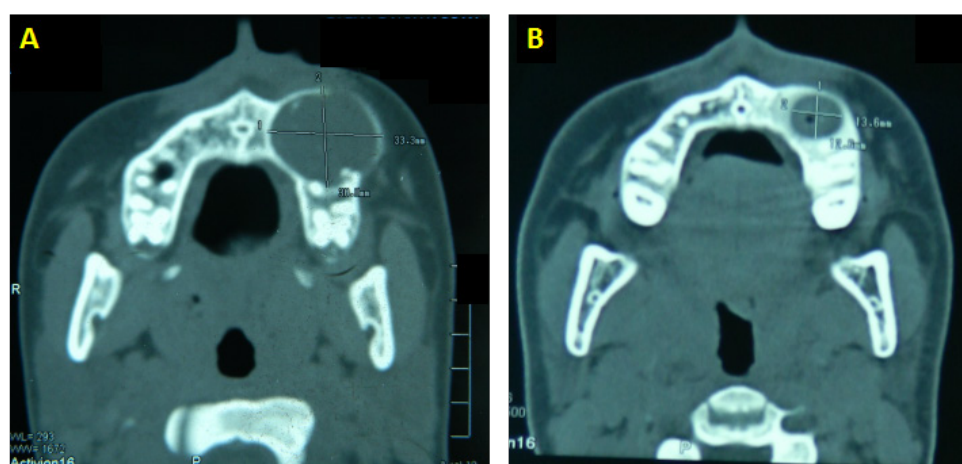


Figure 2. Axial CT showing (A) pre-marsupialization and (B) 6-month post-marsupialization reduction of maxillary radicular cyst.

Table 1. Distribution of studied patients among groups (MIMIC, AutoCAD) software, including gender, age, and site.

Variable	MIMIC		AutoCAD		Total		Chi-square Sign.	
	n	%	n	%	n	%		
Gender	Male	8	53.3	8	53.3	16	53.3	>0.05 ns
	Female	7	46.7	7	46.7	14	46.7	
	Total	15	100	15	100	30	100	
Age	Mean± SD	34.13±9.59						
Site	Maxilla	10	66.7	10	66.7	20	66.7	>0.05 ns
	Mandible	5	33.3	5	33.3	10	33.3	
	Total	15	100	15	100	30	100	
Anterior/posterior	Anterior	9	60.0	9	60.0	18	60.0	>0.05 ns
	Posterior	6	40.0	6	40.0	12	40.0	
	Total	15	100	15	100	30	100	
Site	Anterior Mandible	4	26.7	4	26.7	8	26.7	>0.05 ns
	Posterior Mandible	1	6.7	1	6.7	2	6.7	
	Anterior Maxilla	5	33.3	5	33.3	10	33.3	
	Posterior Maxilla	5	33.3	5	33.3	10	33.3	
	Total	15	100	15	100	30	100	

*, **, ***, Significant at p<0.05, <0.01, <0.001; NS, non-significant at p>0.05

Using MIMIC software, the volume (mm³) recorded an average (SD) of 29041.0±94994.5, 10144.6±13761.4, 3275.0±4579.0, and 1984.6±3303.9 mm³ in pre-marsupialization, 3-, 6-, and 9-months post-marsupialization; respectively (Figure, 3-4; Table 1). The largest volume estimated by MIMIC software was 29041.0 in 3 months post-marsupialization, which decreased to 1984.6 following 9 months post-marsupialization with a total change % from the pre-marsupialization volume by -93.2%. The percentage of reduction in cyst volume estimated by Mimic software increased significantly from 65.1% at 3-months, to 88.7% and 93.2% at six- and nine-months post-marsupialization. The change in volume (mm³) estimated by MIMIC software with the follow-up time points was highly significant (p<0.001), as revealed by Friedman's test and regression trendline. The regression trendline proved a significant inverse change of volume with time (Figure 3A).

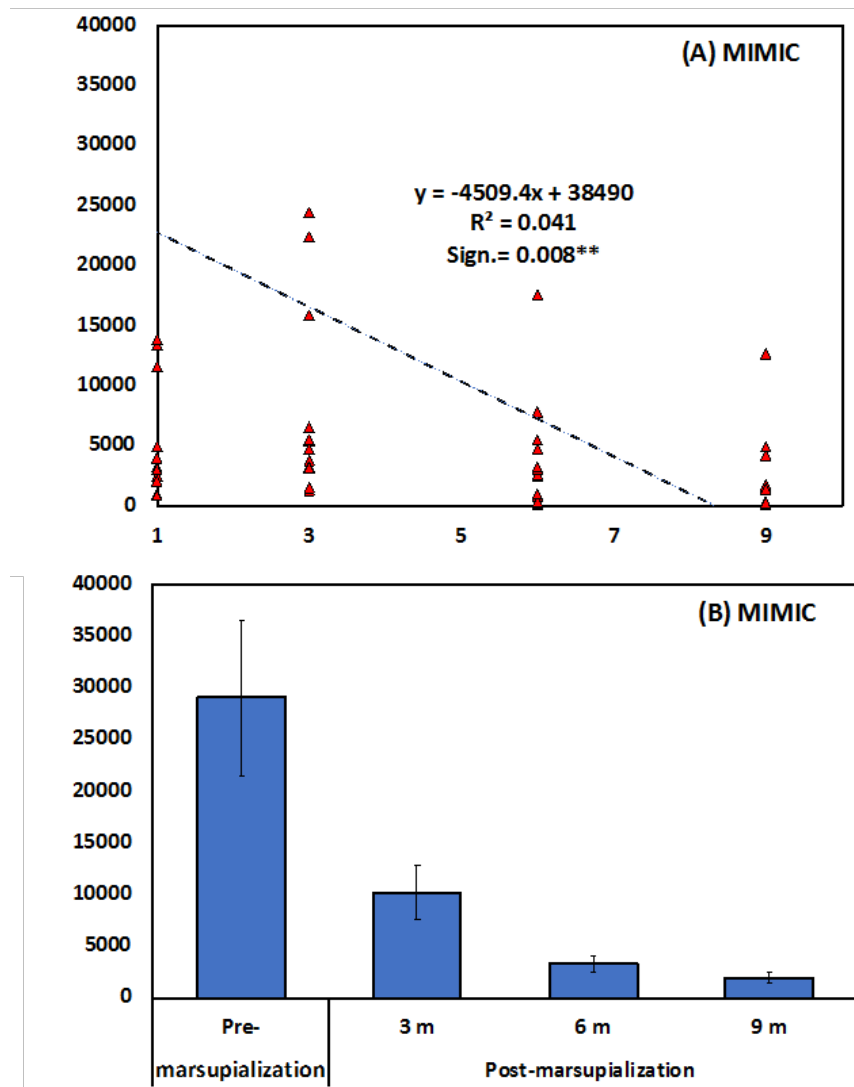
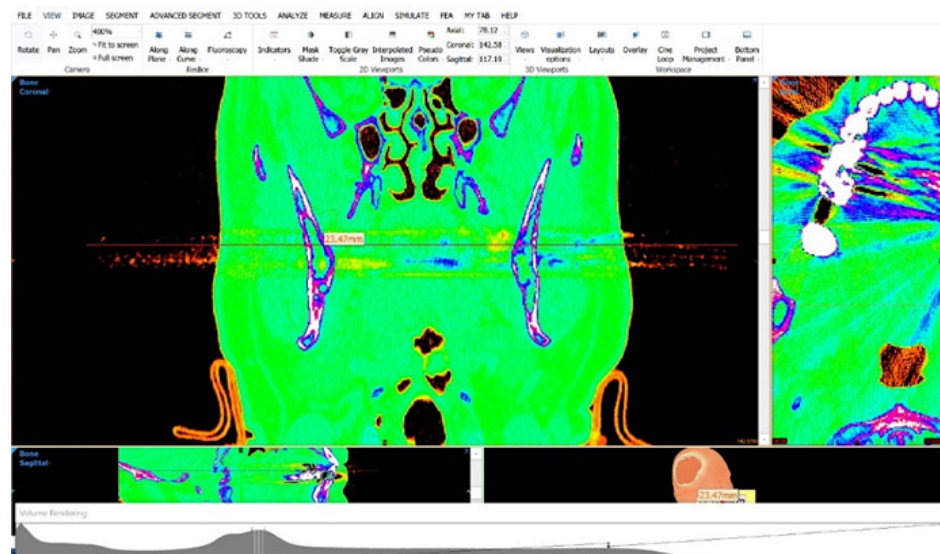


Figure 3. (A) regression trendline showing the change in volume mm3 with follow-up timepoints, (B) bar chart showing the volume mm3 at different time points. Volume estimated by MIMIC software.



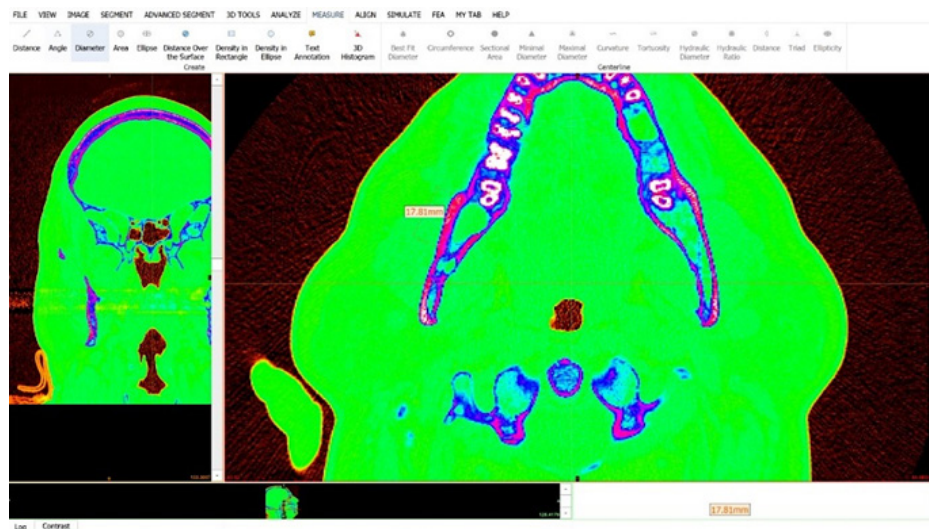


Figure 4. Mimics software measuring 3d volume of cyst pre and 3-month post-marsupialization. The lesion profile is outlined on each slice in 3 spatial planes, providing a 3-dimensional rendering of the cyst. Using AutoCAD software, the volume (mm³) estimated an average (SD) of 29037.9±94.994, 10137.8±13759.9, 3276.6±4579.1, 1984.4±3303.7 mm³ in pre-marsupialization, 3-, 6-, and 9-months post-marsupialization; respectively (Figure, 5-6)

Table 1). The largest volume estimated by AutoCAD software was 29037.9 mm³ recorded in 3 months post-marsupialization, which decreased to 1984.4 following 9 months post-marsupialization with a total change % from the pre- volume of -93.2%. The percentage of reduction in cyst volume estimated by autoCAD software increased significantly from 65.1% at 3-months, to 88.7% and 93.2% at six- and nine-months post-marsupialization. The change in volume (mm³) estimated by AutoCAD software with the follow-up time points was highly significant ($p < 0.001$), as revealed by Friedman’s test and regression trendline. The regression trendline revealed a significant inverse change of volume with time (Figure 5A).

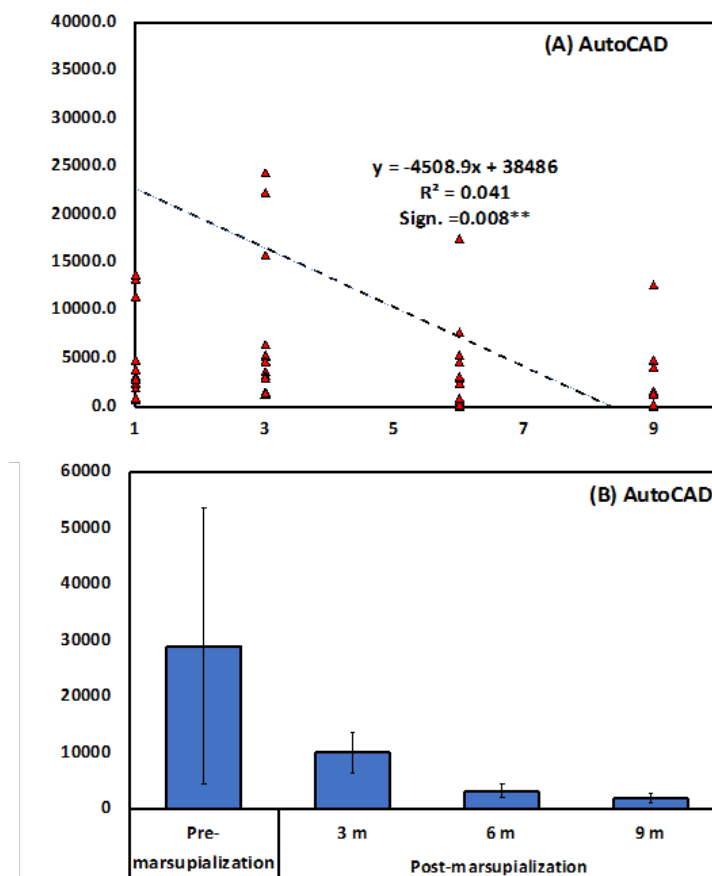


Figure 5. (A) regression trendline showing the change in volume mm³ with follow-up timepoints, (B) bar chart showing the volume mm³ at different time points, volume estimated by AutoCAD software.

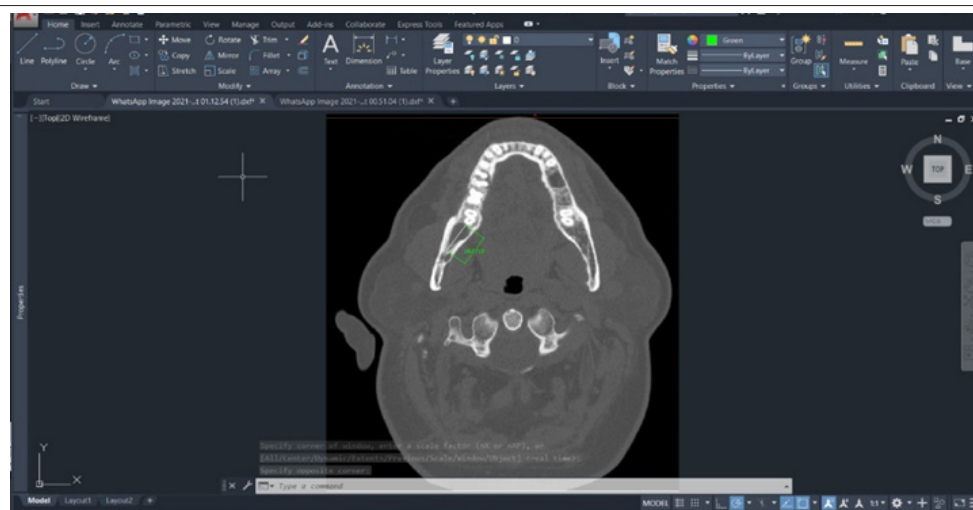


Figure 6. AutoCAD used to measure cyst volume pre and 3 months post-marsupialization. the lesion profile was outlined on each slice in 3 spatial planes, providing a 3- dimensional rendering of the cyst.

The difference between measures carried out by MIMIC and AutoCAD software was non-significant ($p>0.05$) at all checked follow-up time points (pre-, 3-, 6-, 9- months post-marsupialization) as revealed by Mann-Whitney U.

Table 2. Volume (mm³) in pre- and post- marsupialization as estimated by both MIMIC and AutoCAD software.

Group		Volume in mm ³				Friedman's Test, sign.
		Pre-marsupialization	Post-marsupialization Volume in mm ³			
			3 m	6 m	9 m	
MIMIC	Mean	29041.0	10144.6	3275.0	1984.6	<0.001***
	SD	94994.5	13761.4	4579.0	3303.9	
	Change (%) of pre-		-65.07	-88.72	-93.17	
AutoCAD	Mean	29037.9	10137.8	3276.6	1984.4	<0.001***
	SD	94994.9	13759.9	4579.1	3303.7	
	Change (%) of pre-		-65.09	-88.72	-93.17	
Mann-Whitney U		>0.05 ns	>0.05 ns	>0.05 ns	>0.05 ns	
Repeated measures ANOVA						
	Source of variation	F-ratio	p-value			
	Corr. Model	0.87	>0.05 ns			
	Groups	0.00	>0.05 ns			
	Time	2.02	>0.05 ns			
	Groups x Time	0.00	>0.05 ns			

*, **, ***, Significant at $p<0.05$, <0.01 , <0.001 ; NS, non-significant at $p>0.05$

According to repeated-measures analysis of variance (ANOVA), the overall differences between MIMIC and AutoCAD software measures was non-significant ($p>0.05$) at all checked follow-up time points (pre-, 3-, 6-, 9- months post-marsupialization) (Table 2).

Table (3) and Figure (7) represent the average volume (mm^3) with a linear trendline to assess the inter software agreement. There was high internal consistency in intra-examiner estimate agreement (between MIMIC and AutoCAD) regarding Cronbach's alpha value of 1.00, interclass correlation (ICC) of 1.00 (sign. $<0.001^{***}$). Furthermore, there are a highly significant high internal consistency and reliability in inter-software (between software Mimic and AutoCAD) agreement regarding standard resolution and high resolution see table (3). Regression trendline between MIMIC and AutoCAD estimated volumes which showed a coefficient of 1.0 and a highly significant correlation and agreement (Figure, 7).

Table (3). Results of Cronbach's alpha and Inter-Class Correlation Coefficient (ICC) for intra-examiner agreement between MIMIC and AutoCAD software in estimating volume (mm^3).

Software	Volume (mm^3)		Intra-examiner reliability (Cronbach's alpha)		
	Mean	SD	Cronbach's alpha	ICC	Sign.
MIMIC	11111.3	48088.8	1.00	1.00	$<0.001^{***}$
AutoCAD	11109.26	48088.6			
Total	22220.5	96177.4			

*, **, ***, Significant at $p<0.05$, <0.01 , <0.001 ; NS, non-significant at $p>0.05$

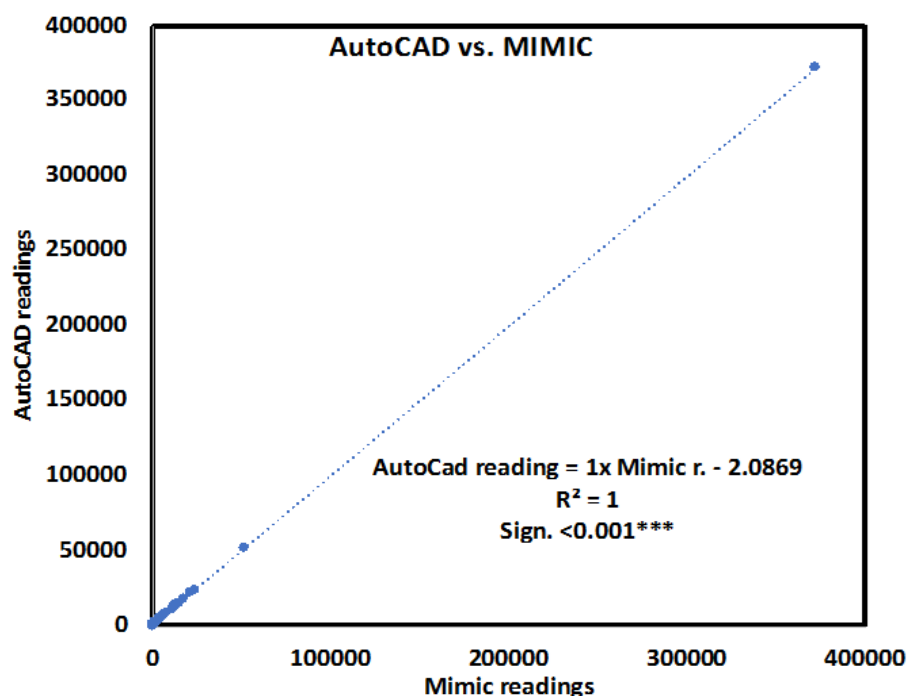


Figure 7. Regression trendline showing the linear interrelationships between volume measured MIMIC software versus AutoCAD measures.

DISCUSSION

Radiological follow-up of cyst volume after marsupialization is of paramount importance in order to measure the rate of volume reduction and the time for enucleation if needed [21]. While bidimensional evaluation can assess volume reduction over time, its shortcomings include inaccurate discrimination of cyst border and the inability to assess the cyst relation with the surrounding vital structures [22]. Thus, 3D imaging has become the modality of choice for preoperative assessment of cyst volume and diameter, which allows for accurate measurement of the cyst volume, demonstrates the cyst border, and evaluates the anatomical relations of the cyst [12]. Cone-beam CT scan is widely utilized in the preoperative assessment and planning of maxillofacial cysts treatment [23]. Despite that the use of cone-beam CT does not increase the cost of surgery-related resources and postoperative management plan, the cost of cone-beam CT itself is high compared to traditional imaging [19]. This cost can increase substantially when regular postoperative follow-up is needed, as in the case of marsupialization.

Therefore, multi-slice CT scan is widely used in limited-resources countries to regularly evaluate the patients after marsupialization, despite its lower accuracy than cone-beam CT [24]. Thus, it is imperative to enhance the feasibility and accuracy of a multi-slice CT scan. Over the recent years, a number of software were designed for monitoring volume reduction and bony defects after marsupialization [25].

Computer-aided design, using AutoCAD software, can represent a promising, inexpensive modality for improving multi-slice CT monitoring of volumetric reduction after marsupialization [26]. Previous reports demonstrated that this tool could enhance postoperative assessment and assess the need and timing of second procedure [27]. However, only few studies assessed the utilization of AutoCAD software in assessment of volume reduction and bone density increase in patients with maxillofacial cysts undergoing marsupialization.

In the present study, we demonstrated the feasibility of AutoCAD software in constructing 3D anatomical images for assessment of the volume reduction for up to nine months after marsupialization. Our results showed the mean percentage of reduction in cyst volume increased significantly from 65.1 % at three months to 88% and 93.2% at six and nine months, respectively.

Such findings run in agreement with a recent report by Consolo and colleagues [25], in which the computer-aided design was effective in monitoring the volumetric changes after marsupialization. The same findings were reported in 2019 report by Riachi and colleagues [28].

Likewise, Asutay and colleagues [12] showed that 3D reconstruction software was useful in monitoring the reduction in cyst volume after surgery. Other reports showed similar results [29-30].

Concerning the significance of changes in volume over the follow-up period, our results run in parallel with Mousa and Adawy [31], who showed significant decrease in the cyst volume over six months duration. Similarly, Enislidis and colleagues [32] and Anavi and colleagues [33] reported a reduction by more than 90% of the cysts over a nine months period. The same results were reported by Lizio *et al* [34].

To the best of our knowledge, our study is one of a limited number of studies that explore the utilization of AutoCAD software in assessment of volume reduction in patients with maxillofacial cysts undergoing marsupialization. Nonetheless, we acknowledge the existence of certain limitations.

We used multi-slice CT for radiological evaluation of the patients; previous reports indicated that the multi-slice CT had higher dose exposure than cone-beam CT and, thus, it can increase the risk of dose-dependent adverse events [35-36]. Besides, the study was limited by the relatively small sample size and being a single center experience.

CONCLUSION

In conclusion, computer-aided assessment of post-marsupialization volume reduction of maxillofacial cysts through AutoCAD software is a readily-available, easy-to-use, cheap, and accurate option. We demonstrated the feasibility of AutoCAD software in constructing 3D anatomical images for assessment of the volume reduction for up to nine months after marsupialization. Future studies with larger sample size and multi-center collaboration are still needed to confirm our findings.

CONFLICT OF INTEREST

The authors declare no conflict of interest.

REFERENCES

1. Shear M, Speight P, editors. *Cysts of the Oral and Maxillofacial Regions* 2007.
2. Paul S, Kapoor V, Kumar M, Narula R, Kapoor V, Kapoor U. A clinical study of cysts of the maxillofacial region; and an assessment of clinico-radiologico-pathological variables affecting the formulation of a comprehensive patient need based treatment plan. *Indian J Dent.* 2014;5(2):69-74.
3. Nyimi BF, Yifang Z, Liu B. The Changing Landscape in Treatment of Cystic Lesions of the Jaws. *J Int Soc Prev Community Dent.* 2019;9(4):328-37.

4. Buchbender M, Neukam FW, Lutz R, Schmitt CM. Treatment of enucleated odontogenic jaw cysts: a systematic review. *Oral Surg Oral Med Oral Pathol Oral Radiol*. 2018;125(5):399-406.
5. Manor E, Kachko L, Puterman MB, Szabo G, Bodner L. Cystic lesions of the jaws - a clinicopathological study of 322 cases and review of the literature. *Int J Med Sci*. 2012;9(1):20-6.
6. Scholl RJ, Kellett HM, Neumann DP, Lurie AG. Cysts and cystic lesions of the mandible: clinical and radiologic-histopathologic review. *Radiographics*. 1999;19(5):1107-24.
7. Kolokythas A, Fernandes RP, Pazoki A, Ord RA. Odontogenic keratocyst: to decompress or not to decompress? A comparative study of decompression and enucleation versus resection/peripheral ostectomy. *J Oral Maxillofac Surg*. 2007;65(4):640-4.
8. Pogrel MA. Treatment of keratocysts: the case for decompression and marsupialization. *J Oral Maxillofac Surg*. 2005;63(11):1667-73.
9. Pogrel MA, Jordan RC. Marsupialization as a definitive treatment for the odontogenic keratocyst. *J Oral Maxillofac Surg*. 2004;62(6):651-5; discussion 5-6.
10. Huang IY, Lai ST, Chen CH, Chen CM, Wu CW, Shen YH. Surgical management of ameloblastoma in children. *Oral Surg Oral Med Oral Pathol Oral Radiol Endod*. 2007;104(4):478-85.
11. Oliveros-Lopez L, Fernandez-Olavarria A, Torres-Lagares D, Serrera-Figallo MA, Castillo-Oyague R, Segura-Egea JJ, et al. Reduction rate by decompression as a treatment of odontogenic cysts. *Med Oral Patol Oral Cir Bucal*. 2017;22(5):e643-e50.
12. Asutay F, Atalay Y, Turamanlar O, Horata E, Burdurlu M. Three-Dimensional Volumetric Assessment of the Effect of Decompression on Large Mandibular Odontogenic Cystic Lesions. *J Oral Maxillofac Surg*. 2016;74(6):1159-66.
13. Song IS, Park HS, Seo BM, Lee JH, Kim MJ. Effect of decompression on cystic lesions of the mandible: 3-dimensional volumetric analysis. *British Journal of Oral and Maxillofacial Surgery*. 2015;53(9):841-8.
14. Dong C, Klimek P, Abächerli C, De Rosa V, Krieg AH. Percutaneous cyst aspiration with injection of two different bioresorbable bone cements in treatment of simple bone cyst. *Journal of Children's Orthopaedics*. 2020;14(1):76-84.
15. World Medical Association Declaration of Helsinki. Ethical principles for medical research involving human subjects. *Bull World Health Organ*. 2001;79(4):373-4.
16. Faul F, Erdfelder E, Buchner A, Lang A-G. Statistical power analyses using G*Power 3.1: Tests for correlation and regression analyses. *Behav Res Methods*. 2009;41(4):1149-60.
17. Faul F, Erdfelder E, Lang A-G, Buchner A. G*Power 3: a flexible statistical power analysis program for the social, behavioral, and biomedical sciences. *Behav Res Methods*. 2007;39(2):175-91.
18. Aljandali A. *Quantitative Analysis and IBM SPSS Statistics: A Guide for Business and Finance*: Springer Publishing Company, Incorporated; 2016.
19. Daniel WW, Cross CL. *Biostatistics: a foundation for analysis in the health sciences*: Wiley; 2018.
20. Gerstman BB. *Basic biostatistics : statistics for public health practice*. Sudbury, Mass.: Jones and Bartlett Publishers; 2008.
21. Bodner L, Bar-Ziv J. Characteristics of bone formation following marsupialization of jaw cysts. *Dentomaxillofac Radiol*. 1998;27(3):166-71.
22. Zhao Y, Liu B, Han QB, Wang SP, Wang YN. Changes in bone density and cyst volume after marsupialization of mandibular odontogenic keratocysts (keratocystic odontogenic tumors). *J Oral Maxillofac Surg*. 2011;69(5):1361-6.
23. Deana NF, Alves N. Cone Beam CT in Diagnosis and Surgical Planning of Dentigerous Cyst. *Case Rep Dent*. 2017;2017:7956041.
24. Petersen LB, Olsen KR, Christensen J, Wenzel A. Image and surgery-related costs comparing cone beam CT and panoramic imaging before removal of impacted mandibular third molars. *Dentomaxillofac Radiol*. 2014;43(6):20140001.
25. Consolo U, Bellini P, Melini GM, Ferri A, Lizio G. Analysis of Marsupialization of Mandibular Cysts in Improving the Healing of Related Bone Defects. *J Oral Maxillofac Surg*. 2020;78(8):1355.e1-e11.
26. Ciobanu O. The use of a Computer Aided Design (CAD) environment in 3D reconstruction of anatomic surfaces. *Stud Health Technol Inform*. 2006;119:102-4.
27. Koivuholma A, Aro K, Mäkitie A, Salmi M, Mirtti T, Hagström J, et al. Three-Dimensional Presentation of Tumor Histopathology: A Model Using Tongue Squamous Cell Carcinoma. *Diagnostics (Basel)*. 2021;11(1).

28. Riachi F, Khairallah CM, Ghosn N, Berberi AN. Cyst volume changes measured with a 3D reconstruction after decompression of a mandibular dentigerous cyst with an impacted third molar. *Clin Pract.* 2019;9(1):1132.
29. Shudou H, Sasaki M, Yamashiro T, Tsunomachi S, Takenoshita Y, Kubota Y, et al. Marsupialisation for keratocystic odontogenic tumours in the mandible: longitudinal image analysis of tumour size using 3D visualised CT scans. *Int J Oral Maxillofac Surg.* 2012;41(3):290-6.
30. Song IS, Park HS, Seo BM, Lee JH, Kim MJ. Effect of decompression on cystic lesions of the mandible: 3-dimensional volumetric analysis. *Br J Oral Maxillofac Surg.* 2015;53(9):841-8.
31. Mousa IK, Adawy AM. The Shrinkage Pattern of Odontogenic Cyst After Surgical Decompression. *Al-Azhar Assiut Dental Journal.* 2020;3(2):89-97.
32. Enislidis G, Fock N, Sulzbacher I, Ewers R. Conservative treatment of large cystic lesions of the mandible: a prospective study of the effect of decompression. *Br J Oral Maxillofac Surg.* 2004;42(6):546-50.
33. Anavi Y, Gal G, Miron H, Calderon S, Allon DM. Decompression of odontogenic cystic lesions: clinical long-term study of 73 cases. *Oral Surg Oral Med Oral Pathol Oral Radiol Endod.* 2011;112(2):164-9.
34. Lizio G, Sterrantino AF, Ragazzini S, Marchetti C. Volume reduction of cystic lesions after surgical decompression: a computerised three-dimensional computed tomographic evaluation. *Clin Oral Investig.* 2013;17(7):1701-8.
35. Lizio G, Tomaselli L, Landini L, Marchetti C. Dentigerous cysts associated with impacted third molars in adults after decompression: a prospective survey of reduction in volume using computerised analysis of cone-beam computed tomographic images. *Br J Oral Maxillofac Surg.* 2017;55(7):691-6.
36. Nakamura N, Mitsuyasu T, Mitsuyasu Y, Taketomi T, Higuchi Y, Ohishi M. Marsupialization for odontogenic keratocysts: long-term follow-up analysis of the effects and changes in growth characteristics. *Oral Surg Oral Med Oral Pathol Oral Radiol Endod.* 2002;94(5):543-53.