

Effect of Apitoxin versus Hyaluronic Acid in Treatment of Induced Temporomandibular Joint Osteoarthritis in Albino Rats: An Experimental Study.

Manar A. Selim¹, Ghada Mohammed said Hamed², Mona Dahab³, Hamdy A. Hendawy⁴, Ahmed Abdelmohsen younis⁵

Original Article

¹ Associate professor of Oral Biology, Faculty of dentistry, Suez Canal University.

² Lecturer of Oral Biology, Faculty of dentistry, Suez Canal University.

³ Lecturer of Oral Biology, Faculty of dentistry, Fayoum University.

⁴ Lecturer of anesthesia, Faculty of Medicine, Suez Canal University.

⁵ Lecturer of oral & maxillofacial surgery, Faculty of dentistry, Suez Canal University.

ABSTRACT

Aim: Mto evaluate the potential effect of apitoxin versus hyaluronic acid in treatment of temporomandibular joint (TMJ) osteoarthritis (OA) in male albino rats through histological examination.

Material and methods: Twenty-four rats were separated into three groups (8 rats each): Group I (control group): TMJs with untreated induced arthritis. Group II: with induced TMJs arthritis that were subjected to 50µl intra-articular injection of hyaluronic acid (HA), once a week on days 7, 14, 21 and 28 for 4 weeks. Group III: with induced TMJs arthritis that were subjected to intra-articular injection of bee venom (Apitoxin) solution three times per week for four weeks with dose of 0.5 ml per injection. At the end of the experiment all rats were euthanized, TMJs samples were obtained from different groups. Sections of TMJs specimens were stained with hematoxylin and eosin stain for histopathological examination.

Results: Multiple degenerative histological features were revealed in group I untreated OA rats. In group II treated with intra-articular injection of HA, signs of improvement were observed retaining many of TMJ normal histological structure as thickness of fibrous, proliferative, hypertrophic layers with well organized chondrocytes. While group III treated with apitoxin showed increase in thickness of fibrous layer inspite of the significant retrieval of proliferative and hypertrophic layers of chondrocytes nearly to normal distribution with no empty lacunae.

Key Words: TMJ osteoarthritis, Hyaluronic acid, Apitoxin

Received: 1 June 2023, **Accepted:** 6 June 2023.

Corresponding Author: Manar A. Selim, Associate professor of Oral Biology, Faculty of dentistry, Suez Canal University **Mobile:** 00201222660475, **E-mail:** manar3bdel3ziz@yahoo.com

ISSN: 2090-097X, July 2024, Vol. 15, No. 3

INTRODUCTION:

Osteoarthritis (OA) of the temporomandibular joint (TMJ) is supposed to be a mix of joint degenerative disease and joint discomfort^[1]. It is a condition that affects the entire joint. The TMJ OA etiology is multifactorial^[2].

There are two categories of TMJ arthritic conditions: high-inflammatory disorders and low-inflammatory disorders. Metabolic arthritic illnesses, rheumatoid arthritis and infectious arthritis have been categorized as high-inflammatory disorders, whereas post-traumatic arthritis and OA have been categorized as low-inflammatory disorders^[3].

Because the etiological reasons for TMJ OA are so complicated, a multidisciplinary approach is necessary for their treatment^[4]. The reduction of TMJ discomfort, restoration of normal mandibular motions and enhancement

of patients' quality of life have been stated as the three main goals for the therapy of TMJ OA^[5].

Adjunctive therapy includes rheumatic arthritis (RA) symptomatic medications such analgesics, nonsteroidal anti-inflammatory medicines, disease-modifying antirheumatic agents and steroids that act to manage pain and inflammation. It is recommended to use corticosteroids^[6].

Due to the drugs' numerous drawbacks, including their expensive prices and critical side effects, their use is restricted. Consequently, a novel therapeutic approach is needed to treat rheumatic arthritis that not only delays joint degradation but also has lower costs and less side effects^[7].

Intra-articular injections of hyaluronic acid (HA).

corticosteroids (CS) or growth factors, arthrocentesis alone and ultimately the combination of arthrocentesis and intra-articular injections are less invasive surgical techniques used to treat TMJ OA. The invasive surgical techniques include arthroscopy and open joint operations, such as discectomy, high condylectomy and arthroplasty [8].

N-acetyl glucosamine and glucuronic acid are repeated in hyaluronic acid (HA), an anionic disaccharide, it is the only nonsulfated glycosaminoglycan (GAG) and a member of the glycosaminoglycan family. Up to 25,000 repeating disaccharide units can be found in it. HA typically has a high molecular weight of up to 107 Da. [9]

The extracellular matrix of cartilage and synovial fluid both naturally contain hyaluronic acid. It is also regarded as one of nature's most hydrophilic molecules [7].

A fluid, light-yellow substance called apitoxin is released by excited bees. This compound contains melittin, phospholipase A2, histamine, hyaluronidase, catecholamine and serotonin [10].

The most significant therapeutic component, melittin, makes up around half of the dry weight of apitoxin. Numerous chemical components of apitoxin (bee venom) cause allergic reactions when it enters the human body and in critical cases resulted in anaphylactic shock [12]. Bee venom (BV), despite being hazardous, has been used for medicinal purposes in a number of clinical settings [13].

Bee venom therapy (BVT) is used to treat a variety of illnesses, but it is particularly well-known for being useful for musculoskeletal illnesses like arthritis, immune-related diseases and arthralgia since bee venom has analgesic and anti-inflammatory properties [14].

BV injection therapy suppressed immunological responses in a type-II collagen-induced arthritis. TNF- production was significantly decreased in the BV group when compared to the control group, although IL-1 production remained constant. [15].

As a result of the decreased expression of NF-kB (p65) and TNF- α in the synovial membrane of the hind paw, the combination of methotrexate and bee venom enhanced the anti-arthritic effects of methotrexate and decreased the hepatotoxicity caused by methotrexate. [16]

A different treatment option for TMJ osteoarthritis, BV injections demonstrated anti-arthritic and anti-nociceptive effects in rats with arthritis. [17]

AIM OF THE STUDY:

The present study aims to estimate the potential effect of apitoxin versus hyaluronic acid as a potential therapy in the treatment of temporomandibular joint osteoarthritis in male albino rats through histological examination using hematoxyline & eosin stain.

MATERIAL & METHODS:

Materials that were used in the present:

- Hyaluronic acid (HA) composed of Sodium hyaluronate, 1.0% manufactured by Curavisc.
- Apitoxin composed of 10 ml Bee Venom solution manufactured by APITOXIN Co., Sweden
- Complete Freund's adjuvant (CFA), Each mL contains 1 mg of mycobacterium tuberculosis, 0.15 mL mannide monooleate and 0.85 mL paraffin oil manufactured by Sigma Aldrich.

Methods

- Sample size calculation:

Calculation of sample size was performed using G*Power version 3.1.9.2, Faul et al, (2007) [18]. The effect size d was 0.63 using alpha (α) level of 0.15 and Beta (β) level of 0.15, i.e., power = 85%; the expected sample size (n) should be 24 samples (rats) for the present study and were separated equally into three groups (8 rats each).

- Ethics consideration:

The present study were commenced after the approval of the Research Ethics Committee (REC) of the Faculty of Dentistry, Suez Canal University (no. 613/2023). This investigation were carried out on 24 adult male rats (average weight 120 g). Rats were housed separately in sterile metal cages under standard conditions, environmental temperature (25°C) and controlled lightening receiving a standard laboratory diet as well as water.

Samples grouping and study procedures:

Induction of osteoarthritis:

Induction of osteoarthritis were carried out in the right TMJs of all rats by a single intra-articular injection of 50 μ l of Complete Freund's Adjuvant (CFA), diluted 1:1 (saline: oil), CFA utilized was of a concentration of 1mg/ml heat killed mycobacterium tuberculosis. The induction day was considered 0 day [19].

Twenty-four rats were haphazardly allocated into three groups (8 rats each):

Group I (control group): consisted of 8 rats TMJs with untreated induced arthritis.

Group II: involved 8 rats with induced TMJs arthritis that were subjected to a 50 μ l intra-articular injection of hyaluronic acid (HA), once a week for total of four injections on days 7, 14, 21 and 28. HA were supplied in the form of pre-filled sterile syringes (single use only). The calculated volume were withdrawn immediately for the intra-articular injections after opening the syringe and any excess will be removed [20].

Group III: involved 8 rats with induced TMJs arthritis that were subjected to intra-articular injection of bee venom (Apitoxin) solution three times every week for 4 weeks with dose of 0.5 ml per injection were utilized [21].

At the end of the present experiment all rats were euthanized under ketamine anesthesia (80 mg/kg, i.p.). Immediately after euthanization, TMJs samples were obtained from different groups, fixed for 2 weeks in 10% formaldehyde solution, decalcified in a solution containing 0.85% NaCl, 10% acetic acid and 10% formalin. The TMJs specimens were then washed appropriately under running water, dehydrated by shifting through ascending degrees of alcohol, then transmitted to xylene to free the specimens from alcohol. They were then embedded in paraffin blocks and cut in longitudinal sections of 34- μm thickness. Sections were stained with hematoxylin and eosin for histopathological examination [22].

Statistical analysis

All data for this experimental study were collected, calculated, tabulated and statistically analyzed using the following statistical tests. A normality test (Kolmogorov-Smirnov) was done to check normal distribution of the samples. Descriptive statistics were calculated in the form of Mean \pm Standard deviation (SD). One-way ANOVAs were used to compare between groups in each variable under study. Bonferroni's as post hoc test was performed for the evaluation of statistical significances among the groups. P value ≤ 0.05 is considered statistically significant. All Statistical analysis was performed using the computer program SPSS software for windows version 26.0 (Statistical Package for Social Science, Armonk, NY: IBM Corp).

Histopathologic results:

Multiple degenerative histological features were revealed in group I untreated OA rats as marked increase in the thickness of the fibrous tissue layer of both articular surfaces at head of condyle and glenoid fossa and severe reduction in proliferative zone. Irregular articular surface of the condyle with resorbed layers of articular surface forming impeded fissures where pyknotic chondrocytes as well as multiple empty lacunae were seen. Bone marrow cavities were expanded infiltrated with inflammatory cells. Morphological alteration in the disc was also detected as pending and tightening. Folded hyper plastic synovial lining and fat cells were identified beside significant decrease in upper and lower joint space (Fig 1).

In group II treated with intra-articular injection of HA, signs of improvement were observed retaining many of TMJ normal histological structure as thickness of fibrous, proliferative, hypertrophic layers with well-organized chondrocytes. Absence of fatty cells, reduction of inflammatory infiltration and regular synovial lining incompatible with retrodiscal tissue in addition to adequate upper and lower joint space (Fig 2, A&B).

While group III treated with bee venom showed decrease in thickness of fibrous layer compared to group I in addition to significant retrieval of proliferative and hypertrophic layers of chondrocytes nearly to normal distribution with no empty lacunae. Bone marrow cavities were narrower than group I and filled with less inflammatory cells.

reduction of inflammatory infiltration and regular synovial lining incompatible with retrodiscal tissue in addition to adequate upper and lower joint space (Fig 2, A&B).

While group III treated with bee venom showed decrease in thickness of fibrous layer compared to group I in addition to significant retrieval of proliferative and hypertrophic layers of chondrocytes nearly to normal distribution with no empty lacunae. Bone marrow cavities were narrower than group I and filled with less inflammatory cells. Adequate lower joint space appeared between the disc and articular surface of condylar head. Fat cells and folded synovial lining were observed (Fig 2, C&D).

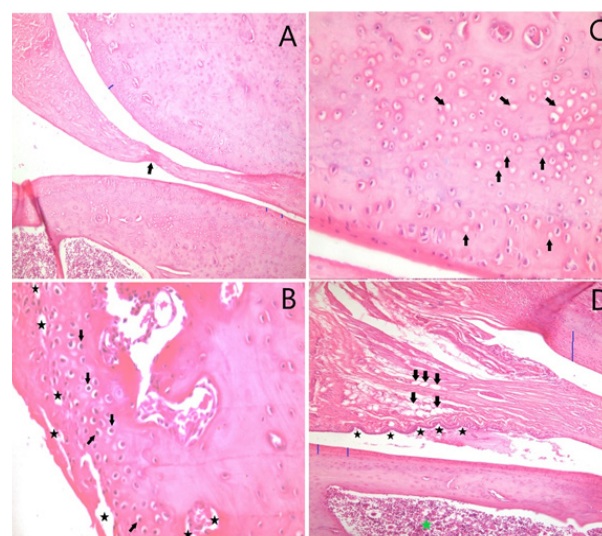


Figure 1: Photomicrographs of sagittal section in rats TMJ from untreated group I OA where (A) showed over thickness of fibrous layer (blue lines), proliferative layer of chondrocytes was hardly detected, pending of disc at central region (arrow) and marked decrease in upper and lower joint space (H&E. orig. mag. 100).(B&C) showing higher magnification of (A): (B) with partial resorbed chondral layers leaving fissure traces (stars) and multiple chondrocytes with pyknotic nuclei (arrows) while (C) revealed several empty chondrocyte lacunae (arrows) (H&E. orig. mag. 400).(D) showed fat cells deposition (black arrows), several folded hyper plastic synovial lining (stars), over thickness of fibrous layer (blue lines) and wide marrow cavities infiltrated with inflammatory cells (green star) (H&E. orig. mag. 100).

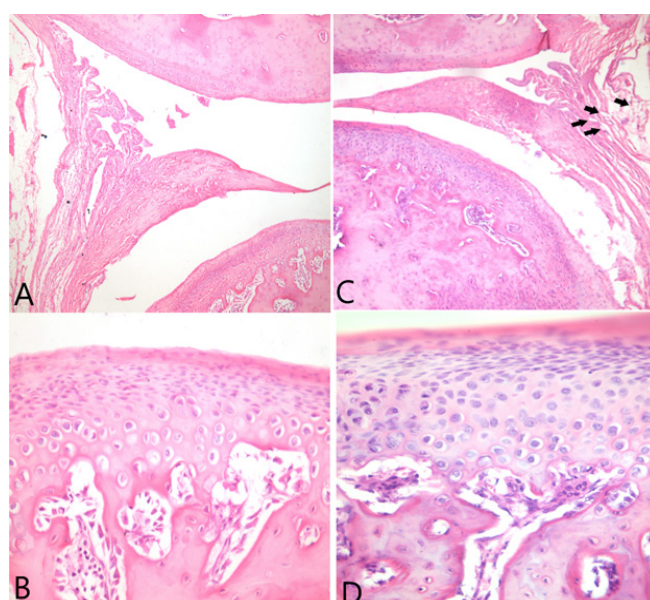


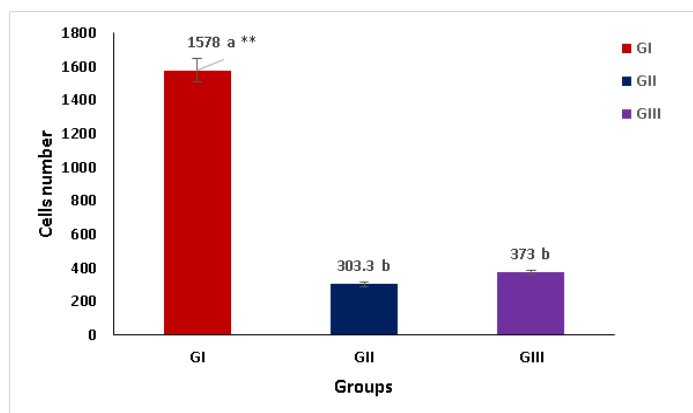
Figure 2: Photomicrographs of sagittal section in rats TMJ from treated groups, figs (A&B) for group II HA, figs (C&D) for group III bee venom where (A) showed nearly normal histological structure for TMJ, absence of fat cells and regular retrodiscal intima (H&E. orig. mag. 100). (B) with higher magnification of (A) revealed less fibrous layer, well distinct chondral layers, and normal marrow width with significant reduction in inflammatory infiltration (H&E. orig. mag. 400). (C) showed reduction in thickness of fibrous layer on both articular surfaces, fatty deposition exists (arrows) and adequate of lower joint space (H&E. orig. mag. 100). (D) with higher magnification of (C) revealed well organized chondrocytes within their matrix and few inflammatory cells existed (H&E. orig. mag. 400).

Statistical results:

The results in table 1, showed that there is significant difference between the studied groups for number of inflammatory cells using one way ANOVA ($F= 922.95$, $P< 0.0001$). Pairwise the statistical comparison showed significant difference between GI with GII and GIII while there is no significant difference between GII with GIII. The high mean values were recorded in GI (1578.0 ± 68.0) followed by GIII (373.0 ± 12.0), while GII was recorded the lowest value (373.0 ± 12.0) (Fig. 3).

Table 1: Showing the statistical comparison between the three groups for the numbers of inflammatory cells

Groups	Mean	SD	Min.	Max.	F test	P values
GI	1578.0 ^a	68.0	1510	1646	922.95	<0.0001**
GII	303.3 ^b	15.5	288	319		
GIII	373.0 ^b	12.0	361	385		
Pair wise comparison used Bonferroni Post Hoc Tests						
	Mean difference	P value	95% Confidence Interval			
			Lower	upper		
GI Vs GII	1274.7	<0.0001**	1165.0	1384.3		
GI Vs GIII	1205.0	<0.0001**	1095.3	1314.7		
GII Vs GIII	-69.7	0.245	-179.3	40.0		



Figure, 3: Showing the comparison between the three groups for the numbers of inflammatory cells

Discussion

The most complex movement in the human body is achieved by the temporomandibular joint (TMJ), a synovial joint.

The present study aims to assess the potential effect of apitoxin as a therapy versus hyaluronic acid in treatment of temporomandibular joint osteoarthritis in albino rats. TMJ specimens of group I untreated OA rats showed multiple degenerative histological features as marked increase in the thickness of the fibrous tissue layer of both articular surfaces at head of condyle and glenoid fossa and severe reduction in proliferative zone. Irregular articular surface of the condyle with resorbed layers of articular surface forming impeded fissures where pyknotic chondrocytes as well as multiple empty lacunae were seen. Bone marrow cavities were expanded infiltrated with inflammatory cells. Morphological alteration in the disc was also detected as pending and tightening. Folded hyperplastic synovial lining and fat cells were identified beside significant decrease in upper and lower joint space.

These results are in accordance with Zarb and Carlsson who reported that progressive cartilage degeneration, subchondral bone remodelling, synovitis and ongoing discomfort are all symptoms of osteoarthritis [23].

The gradual degradation of cartilage is caused by inadequate chondrocytes regulation and a disparity among tissue production and destruction [24]. Chondrocytes control the balance between extracellular matrix (ECM) breakdown and synthesis. Though, this control can be interrupted if synthesis and catabolic activity is not connected [25]. Furthermore, the amount of apoptotic chondrocytes multiplies considerably in osteoarthritis, which is correlated with death receptor and the endoplasmic reticulum pathways [26]. The degeneration of proteoglycans as well as collagen in cartilage results in erosion, cracking and fibrillation in the superficial layer of cartilage [27]. This progression extends to the deeper layer of cartilage and expands to cause erosions over time. The TMJ articular surface displays exceptional adaptability [28].

Hypertrophic chondrocytes stimulate the degradation of the extracellular matrix and ossification of cartilage. This

denatured cartilage adjusts less mechanically to harmful stimuli, such as trauma [29].

Chondrocyte death triggered either by apoptosis or necrosis is presumed to be a crucial feature in the deterioration of osteoarthritic cartilage experimentally or clinically. In a rat model of induced TMJOA, the chondrocytes apoptosis is the obvious characteristic of the early stage of cartilage degradation and the release of cytokines by the apoptotic chondrocytes may contribute to the damage of subchondral bone [30].

In accordance with the current results, Braun et al showed that intense infiltration of inflammatory cells, hyperplastic synovial membrane and thickening of the condylar articular surface with atrophy of fibrocartilage of TMJOA [31].

In group II treated with intra-articular injection of HA, signs of improvement were observed retaining many of TMJ normal histological structure as thickness of fibrous, proliferative, hypertrophic layers with well organized chondrocytes. Absence of fatty cells, reduction of inflammatory infiltration and regular synovial lining incompatible with retrodiscal tissue in addition to adequate upper and lower joint space.

Similar results obtained in study by Altman et al who revealed that hyaluronic acid comprise anti-inflammatory accomplishments by suppressing the activity and production of Matrix metalloproteinases MMPs and pro-inflammatory mediators [32].

In addition, HA permits chondroprotective properties and declined the progress of bone and cartilage degradation. HA motivates proliferation of chondrocytes, production of cartilage matrix as well as inhibition of protease [33]. Intra-articular injection of HA presents lubrication, nutrition in addition to decreasing TMJ mechanical stress [34].

While group III treated with bee venom (BV) showed increase in thickness of fibrous layer inspite of the significant retrieval of proliferative and hypertrophic layers of chondrocytes nearly to normal distribution with no empty lacunae. Bone marrow cavities were narrower but engorged with inflammatory cells. Marked reduction in lower joint space appeared the disc almost fused with articular surface of condylar head. Fat cells and folded synovial lining were observed.

It has been reported that BV, in experimental studies, can enhance rheumatoid arthritis [35]. Phonophoresis of BV gel for pelvic inflammation significantly decreased the level of C-reactive protein and reduced the intensity of pain.

Due to its anti-inflammatory properties, melittin, a constituent of bee venom, has gained interest as a potential treatment for rheumatoid arthritis [36]. In case studies and clinical evaluations, it also reduced the severity of degenerative osteoarthritis of the knee, elbow and hip joints [37].

According to reports, BV suppresses prostaglandin E2 and COX-2 in the body, indicating that it may be useful for treating joint inflammation in different areas [38]. Particularly, the effects of the treatment have been noted in dogs with hip osteoarthritis, demonstrating that this therapy is effective in both humans and animals [39].

Conclusion: TMJ OA is a degenerative disorder of TMJ distinguished by chronic pain, degradation of cartilage and erosion of subchondral, leading to net loss of matrix and cells. This study highlighted the validity of use of apitoxin (bee venom) injection as a potential different therapy for treatment of TMJ osteoarthritis due to its analgesic and anti-inflammatory effects.

References:

- Schiffman, E.; Ohrbach, R.; Truelove, E.; Look, J.; Anderson, G.; Goulet, J.-P.; List, T.; Svensson, P.; Gonzalez, Y.; Lobbezoo, F.; et al. Diagnostic Criteria for Temporomandibular Disorders (DC/TMD) for Clinical and Research Applications: Recommendations of the International RDC/TMD Consortium Network* and Orofacial Pain Special Interest Group. *J. Oral Facial Pain Headache* 2014, 28, 6–27.
- Wang, X.D.; Zhang, J.N.; Gan, Y.H.; Zhou, Y.H. Current understanding of pathogenesis and treatment of TMJ osteoarthritis. *J. Dent. Res.* 2015, 94, 666–673.
- Mercuri, L.G.; Abramowicz, S. Arthritic Conditions Affecting the Temporomandibular Joint. In *Contemporary Oral Medicine*; Farah, C., Balasubramaniam, R., McCullough, M., Eds.; Springer: Cham, Switzerland, 2017.
- Derwich, M.; Mitus-Kenig, M.; Pawlowska, E. Orally Administered NSAIDs-General Characteristics and Usage in the Treatment of Temporomandibular Joint Osteoarthritis-A Narrative Review. *Pharmaceuticals* 2021, 14, 219.
- Al-Moraissi, E.A.; Wolford, L.M.; Ellis E 3rd Neff, A. The hierarchy of different treatments for arthrogenous temporomandibular disorders: A network meta-analysis of randomized clinical trials. *J. Craniomaxillofac. Surg.* 2020, 48, 9–23.
- Emery P. Treatment of rheumatoid arthritis. *BMJ (Clin Res ed)*. 2006; 332:152–155
- Smolen JS, Steiner G. Therapeutic strategies for rheumatoid arthritis. *Nat Rev Drug Discov.* 2003; 2: 473–488.
- Derwich, M.; Mitus-Kenig, M.; Pawlowska, E. Interdisciplinary Approach to the Temporomandibular Joint Osteoarthritis-Review of the Literature. *Medicina* 2020, 56, 225.
- Iturriaga V, Vásquez B, Manterola C, del Sol M. Role of Hyaluronic Acid in the Homeostasis and Therapeutics of Temporomandibular Joint Osteoarthritis. *Int J Morphol.* 2017;35:870–6.
- Kogan G, Šoltés L, Stern R, Gemeiner P. Hyaluronic acid: A natural biopolymer with a broad range of biomedical and industrial applications. *Biotechnol Lett.* 2007;29:17–25.
- Necas J, Bartosikova L, Brauner P, Kolar J. Hyaluronic acid (hyaluronan): A review. *Vet Med (Praha)*. 2008;53:397–411.
- Ferreira Junior RS, Sciani JM, Marques-Porto R. Africanized honeybee (*Apis mellifera*) venom profiling: seasonal variation of melittin and phospholipase A (2) levels. *Toxicon.* 2010; 3: 355–362
- Yan XB. Bee venom injection in the treatment of rheumatic and rheumatoid arthritis 86 cases. *Chin J Integr Tradit West Med.* 1995; 15: 370.
- Jang S, Kim KH. Clinical Effectiveness and Adverse Events of Bee Venom Therapy: A Systematic Review of Randomized Controlled Trials. *Toxins (Basel)*. 2020 Aug 29;12(9):558.
- Choi M.S., Park S., Choi T., Lee G., Haam K.K., Hong M.C., Min B.I., Bae H. Bee venom ameliorates ovalbumin induced allergic asthma via modulating CD4+CD25+ regulatory T cells in mice. *Cytokine.* 2013;61:256–265.
- Lee JD, Kim SY, Kim TW, Lee SH, Yang HI, Lee DI, Lee YH. Anti-inflammatory effect of bee venom on type II collagen-induced arthritis. *AmJ Chin Med.* 2004; 32: 361–367
- Darwish SF, El-Bakly WM, Arafa HM, El-Demerdash E. Targeting tnf -alpha and nf-kappab activation by bee venom: role in suppressing adjuvant induced arthritis and methotrexate hepatotoxicity in rats. *PLoS One.* 2013; 8: e79284.
- Faul, F., Erdfelder.E.; Georg Lang.A and Buchner. A G*Power 3: A flexible statistical power analysis program for the social, behavioral, and biomedical sciences. *Behavior Research Methods* 2007, 39 (2), 175-191. *Power version 3.1.9.2, University Kiel, Germany. Copyright (c) 1992-2014.
- Yasmine M. Tolba, Samia S. Omar, Dina A. Nagy. A biochemical study of the effect high molecular weight hyaluronic acid in management temporomandibular joint osteoarthritis in rats. *Alexandria Dental Journal.* (2019) Vol.44 Pages:89-92.

20. Lemos GA, Rissi R, Pimentel ER, Palomari ET. Effects of high molecular weight hyaluronic acid on induced arthritis of the temporomandibular joint in rats. *Acta Histochem.* 2015;117:566–75.
21. Kurtoglu C, Gur OH, Kurkcu M, Sertdemir Y, Guler Uysal F, Uysal H. Effect of botulinum toxin-A in myofascial pain patients with or without functional disc displacement *J Oral Maxillofac Surg* 2008; 66: 1644-51.
22. Yaltrık M, Bilgiç B, Yanar K, Palancıoğlu A, Turgut CT. The Effects of Intra-Articular Injections of Botulinum Toxin A on Experimentally Temporomandibular Joint Osteoarthritis Models. *Clin Exp Health Sci* 2018; 8: 9-13.
23. Zarb GA, Carlsson GE. 1999. Temporomandibular disorders: osteoarthritis. *J Orofac Pain.* 13(4):295–306.
24. Li, B.; Guan, G.; Mei, L.; Jiao, K.; Li, H. Pathological Mechanism of Chondrocytes and the Surrounding Environment during Osteoarthritis of Temporomandibular Joint. *J. Cell. Mol. Med.* 2021, 25, 4902–4911.
25. Utreja, A.; Dymont, N.A.; Yadav, S.; Villa, M.M.; Li, Y.; Jiang, X.; Nanda, R.; Rowe, D.W. Cell and Matrix Response of Temporomandibular Cartilage to Mechanical Loading. *Osteoarthr. Cartil.* 2016, 24, 335–344.
26. Yang, H.; Wen, Y.; Zhang, M.; Liu, Q.; Zhang, H.; Zhang, J.; Lu, L.; Ye, T.; Bai, X.; Xiao, G.; et al. MTORC1 Coordinates the Autophagy and Apoptosis Signaling in Articular Chondrocytes in Osteoarthritic Temporomandibular Joint. *Autophagy* 2019, 16, 271–288.
27. Breedveld, F.C. Osteoarthritis—The Impact of a Serious Disease. *Rheumatology* 2004, 43, i4–i8.
28. Milam, S.B. Pathogenesis of Degenerative Temporomandibular Joint Arthritides. *Odontology* 2005, 93, 7–15.
29. Yan, J.; Qin, W.; Xiao, B.; Wan, Q.; Tay, F.R.; Niu, L.; Jiao, K. Pathological Calcification in Osteoarthritis: An Outcome or a Disease Initiator? *Biol. Rev.* 2020, 95, 960–985.
30. Wang XD, Kou XX, He DQ, Zeng MM, Meng Z, Bi RY, Liu Y, Zhang JN, Gan YH, Zhou YH. 2012. Progression of cartilage degradation, bone resorption and pain in rat temporomandibular joint osteoarthritis induced by injection of iodoacetate. *PLoS One.* 7(9):e45036.
31. Braun HJ, Wilcox-Fogel N, Kim HJ, Pouliot AM, Harris HSA, Dragoet LJ. The effect of local anesthetic and corticosteroid combinations on chondrocyte viability. *Knee. Surg. Sports. TraumatolArthrosc.* 2012; 20: 1689–1695.
32. Altman R, Manjoo A, Fierlinger A, Niazi F, Nicholls M. The mechanism of action for hyaluronic acid treatment in the osteoarthritic knee: a systematic review. *BMC Musculoskelet Disord.* 2015;16:321.
33. Campo GM, Avenoso A, Nastasi G, Micali A, Prestipino V, Vaccaro M, et al. Hyaluronan reduces inflammation in experimental arthritis by modulating TLR-2 and TLR-4 cartilage expression. *Biochim Biophys Acta.* 2011;1812:1170–81.
34. Machado E, Bonotto D, Cunali PA. Intra-articular injections with corticosteroids and sodium hyaluronate for treating temporomandibular joint disorders: a systematic review. *Dental Press J Orthod.* 2013;18:128–33.
35. You, D.-S.; Kwon, Y.-D. The Effect of Bee Venom Pharmacopuncture Therapy on the Condition of Different Concentration in Rheumatoid Arthritis Rat Model. *J. Orient. Rehab. Med.* 2011, 21, 101–123.
36. Aufschnaiter, A.; Kohler, V.; Khalifa, S.; El-Wahed, A.A.; Du, M.; El-Seedi, H.; Buttner, S. Apitoxin and Its Components against Cancer, Neurodegeneration and Rheumatoid Arthritis: Limitations and Possibilities. *Toxins* 2020, 12, 66.
37. Heo, D.S.; Keum, D.H. Effect of Intra-articular Bee Venom Injection on Acute Traumatic Arthritis of Elbow Joint: Two Cases Report. *J. Orient. Rehab. Med.* 2005, 15, 171–180.
38. Lim, J.A.; Kim, S.C.; Kim, S.N.; Lee, S.Y.; Moon, H.C.; Shin, M.S.; Kim, H.J.; Koo, S.T.; Choi, S.M. The Clinical Study on Bee Venom Acupuncture Treatment on Osteoarthritis of Knee Joint. *J. Pharmacopunct.* 2005, 20, 73–81.
39. Kim, T.-H.; Kim, B.-Y.; Kim, W.-B.; Kim, K.-S.; Liu, J.; Kim, D.-H. Bee-venom acupuncture treatment of hip osteoarthritis in a dog. *J. Vet. Clin.* 2006, 23, 190–193.
-